



PATIENT

Zoe Walker

PRESENTING CLINICAL SIGNS

History: Grade 1-2/6 murmur. Controlled hyperthyroid; on methimazole. BNP wnl. Assess prior to anesthesia.

SPECIES

Feline

ELECTROCARDIOGRAPHIC FINDINGS *Note: Single lead ECGs are evaluated as a rhythm strip. Morphology/MEA cannot be definitively commented on.

A single lead ECG is available; 50mm/s, 20mm/mV. The average heart rate is 200bpm with a largely regular rhythm. The rhythm is sinus in origin, with a p for every QRS complex and vice versa. The P and QRS morphologies are positive. No ectopic beats, pauses or other dysrhythmias observed. ECG diagnosis: Normal sinus tachycardia.

BREED

DSH

SEX

FS

ECHOCARDIOGRAM FINDINGS

2D, m-mode, color flow and doppler imaging is available. The left ventricular wall is normal in dimension. There is a mildly hyperechoic endocardium consistent with fibrosis. The papillary muscles are mildly remodeled. The left atrium is normal in size. The right atrium is normal in size. The right ventricle appears normal. The mitral valve is normal in structure and mobility. Blood flow through both the LVOT and RVOT is normal in velocity. No pleural or pericardial effusion seen. No obvious cardiac tumors.

AGE

13years

CARDIAC CHART

WEIGHT

6.22lbs

INTERPRETED BY

Maggie Machen Lamy,
DVM, DACVIM
(Cardiology)

FELINE CARDIAC PARAMETERS	BODY WEIGHT (kg)	HR (BPM)	IVSd (cm) (Moise, Pipers)	LVIDd (cm) (Moise, Pipers)	LWVd (cm) (Moise, Pipers)	FS (%)	EF (%)
NORMAL PARAMETER	-----	150-240	0.35-0.55	<2 (mean 1.5)	3.5-0.55	35-67	80-100
PATIENT			0.43	1.1	0.43	60	94y
FELINE CARDIAC PARAMETERS	LA/AO (Boon)	LA/AO HEART BASE (Swe) (Abbott)	LA 2D short axis Base view (cm) (Abbott)		LVOT VEL (m/s)	RVOT VEL (m/s)	E max (m/s)
NORMAL	<1.5	<1.3	<1.2		<1.6	<1.3	<0.9
PATIENT	NM	1.2	1.2y		1.3	1.0	NM
<p><i>*Note: All measurements based upon multi-modal images and methods. An average value is reported.</i> Adapted from June Boon, Veterinary Echocardiography, 1998 Abbott J & MacLean H JVIM 2006;20: 111-119, Moise et al. Am J Vet Res 47:1476, 1986. Pipers et al. Am J Vet Res 40:882, 1979.</p>							

IMAGING PERFORMED BY

Dana Alterman,
RDCS, LVT

HOSPITAL NAME

Eubank Animal Clinic

REFERRING VET

Dr. Smith

INTERPRETATION OF THE FINDINGS & FURTHER RECOMMENDATIONS

Overtly normal geriatric cardiac structure and function. The LV wall thickness is normal and there is no evidence of elevated left atrial pressure. There is mild remodeling and fibrosis of the left ventricular wall, which is likely a normal variant. Serial echocardiography will be necessary to determine progression. Additionally, no cause for the murmur is identified in this study, making it likely physiologic in origin (i.e., secondary to tachycardia, volume changes, etc.). The ECG is normal, with a normal sinus rhythm.

INVOICE

24096

Given these findings, no medications are indicated.

DATE

5/9/22

No cardiac contraindication for general anesthesia. Mild IV fluid restriction is advised. Risk for complication with steroid use typically follows LA dilation, which in this case is low. That being



PATIENT

Zoe Walker

said, any cat can experience unexpected signs of intolerance and monitoring of RR/RE is advised particularly in the initiation phase.

SPECIES

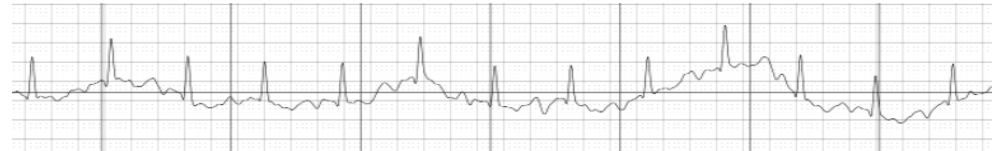
Feline

Recommend recheck echocardiogram in 1 year to reassess murmur origin, and screen for development of disease the pre-existing murmur may mask.

BREED

DSH

IMAGES

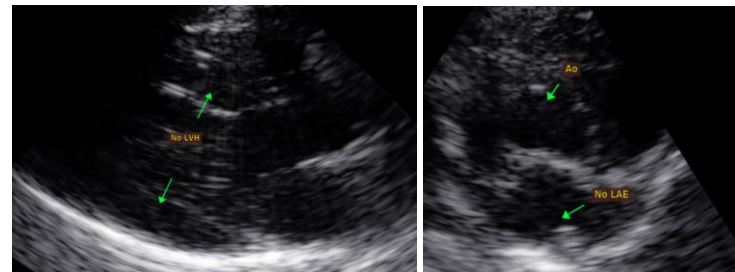


SEX

FS

AGE

13years



WEIGHT

6.22lbs

The information and recommendations provided are based on the images presented by the referring veterinarian. No evaluation can be communicated regarding pathology that was not visible in the image/video clips provided.

INTERPRETED BY

Maggie Machen Lamy,
DVM, DACVIM
(Cardiology)

Thank you for this referral. If the clinical or image interpretation does not parallel your findings or if I can be of any further assistance, please contact me.

Maggie Machen Lamy, DVM
Diplomate of the American College of Veterinary Internal Medicine (Cardiology)
info@sonopath.com

IMAGING PERFORMED BY

Dana Alterman,
RDCS, LVT

HOSPITAL NAME

Eubank Animal Clinic

REFERRING VET

Dr. Smith

INVOICE

24096

DATE

5/9/22